



GHAPP

Gastroenterology & Hepatology
Advanced Practice Providers

2021 Fourth Annual National Conference

September 9-11, 2021

Red Rock Hotel – Las Vegas, NV

TIPS Procedure: Determining Appropriate Candidates

Whitney Steinmetz, DNP, FNP
Presbyterian Medical Group
Albuquerque, NM

Carolyn Catalano, FNP
Rutgers Robert Wood Johnson Medical School
New Brunswick, NJ

Disclosures

All individuals involved in control of the content of continuing education activities provided by the Annenberg Center for Health Sciences at Eisenhower are required to disclose to the audience any real or apparent commercial financial affiliations related to the content of the presentation or enduring material. Full disclosure of all commercial relationships must be made in writing to the audience prior to the activity. All staff at the Annenberg Center for Health Sciences at Eisenhower and Gastroenterology and Hepatology Advanced Practice Providers have no relationships to disclose.

Disclosures

Whitney Steinmetz, DNP, FNP

No financial relationships to disclose.

Carolyn Catalano, FNP

No financial relationships to disclose.

Transjugular Intrahepatic Portosystemic Shunt

- TIPS – a procedure performed by interventional radiologist to decrease portal hypertension. The procedure involves placing an intrahepatic connection between the hepatic and portal vein.
- Multidisciplinary approach is important.
- TIPS is secondary therapy.

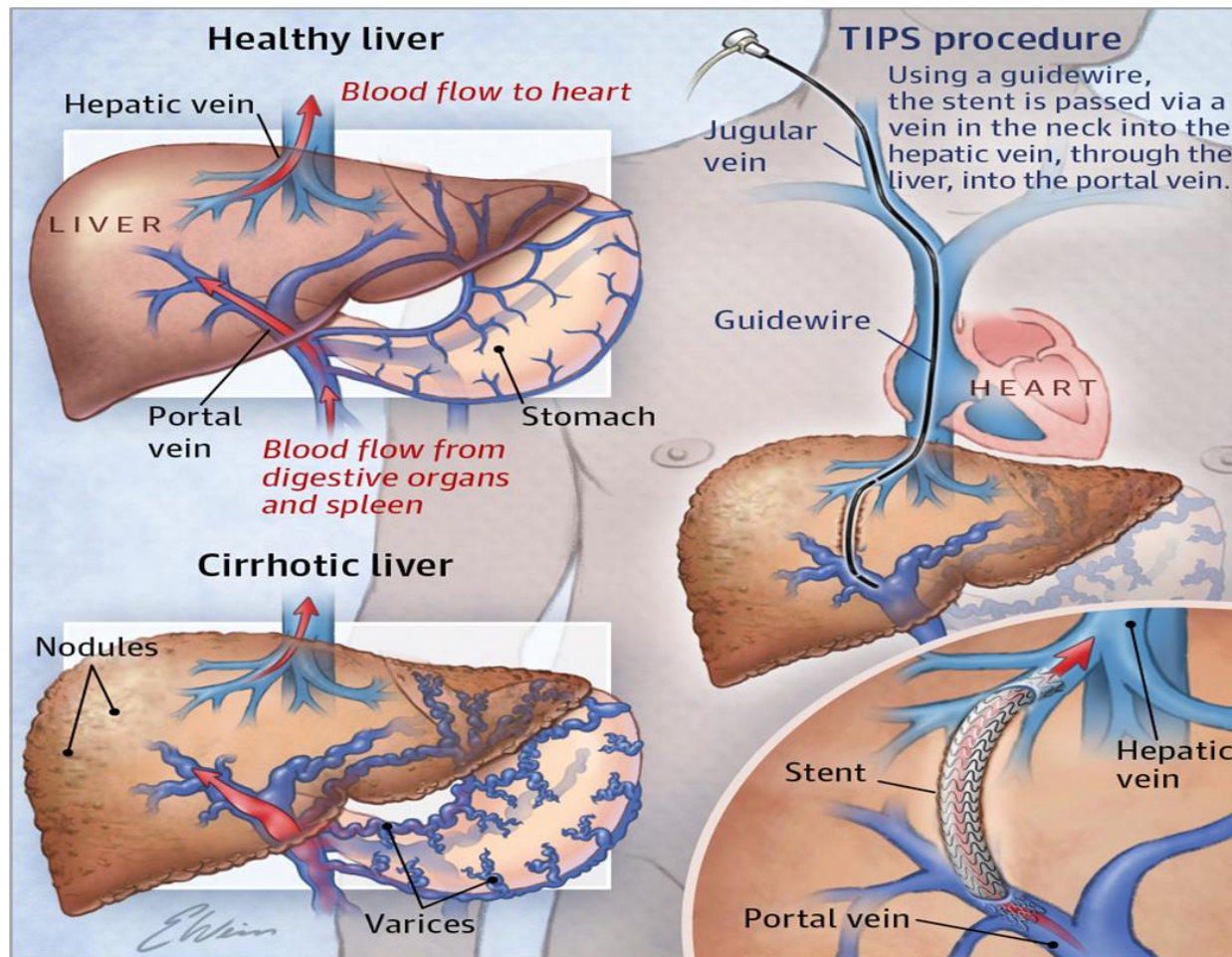
History

- TIPS procedure was first described by Josef Rosch in 1969.
- First performed on a patient by Dr. Colapinto in 1982.
- Started to be widely used in 1990s, technical success rate >97% today.
- Outcomes: 90-100% success rate in variceal control. Improves survival in ascites (TIPS v paracentesis).

Goal of TIPS

- Post TIPS reduction of portosystemic gradient
- Relief of symptoms related to portal hypertension
- Improve quality of life
- Survival benefit in some situations

Transjugular Intrahepatic Portosystemic Shunt (TIPS)



Indication for TIPS

Refractory Ascites

Multiple episodes of variceal bleeding

Refractory variceal bleeding

Acute variceal bleed

Recurrent acute variceal bleed

Uncommon indications: Hepatorenal syndrome and hepatic hydrothorax

Indications: Failure of First Line Therapy

Fail first line (EGD + medications)

- Failure defined as bleeding despite at least 1 endoscopic treatment with endoscopist experienced with EVL
- Consider in patients who cannot tolerate or have complications from beta blockers
- Re-bleed within 120 hours
- EGD prior to TIPS when they present for second upper GI bleed

Refractory Ascites

AASLD recommends TIPS only in patients who are intolerant of repeat large volume paracentesis

Increasing evidence suggests TIPS more effective than paracentesis in controlling ascites and may be associated with survival advantage

Need to meet several criteria:

- Diuretic resistant ascites
- Intolerant of paracentesis or requiring them weekly
- CP class A or B, MELD score <18
- Caregiver present in the home
- Do NOT have alcoholic hepatitis
- Cardiac EF >60%
- No history of severe **spontaneous** hepatic encephalopathy

Pre-Evaluation and Planning

Detailed HPI

CBC, CMP, PT/INR - assuming a full liver workup was done prior.

Abdominal imaging- Triphasic CT or MRI to confirm patency of vessels & roadmap for IR

Echocardiogram

Why is MELD/CPT important?

Absolute Contraindication

Primary prevention of variceal bleeding

Congestive heart failure

Severe tricuspid regurgitation

Severe pulmonary regurgitation

Sepsis

Unrelieved biliary obstruction

Multiple hepatic cyst

Relative Contraindications

HCC

PVT

Moderate
pulmonary HTN

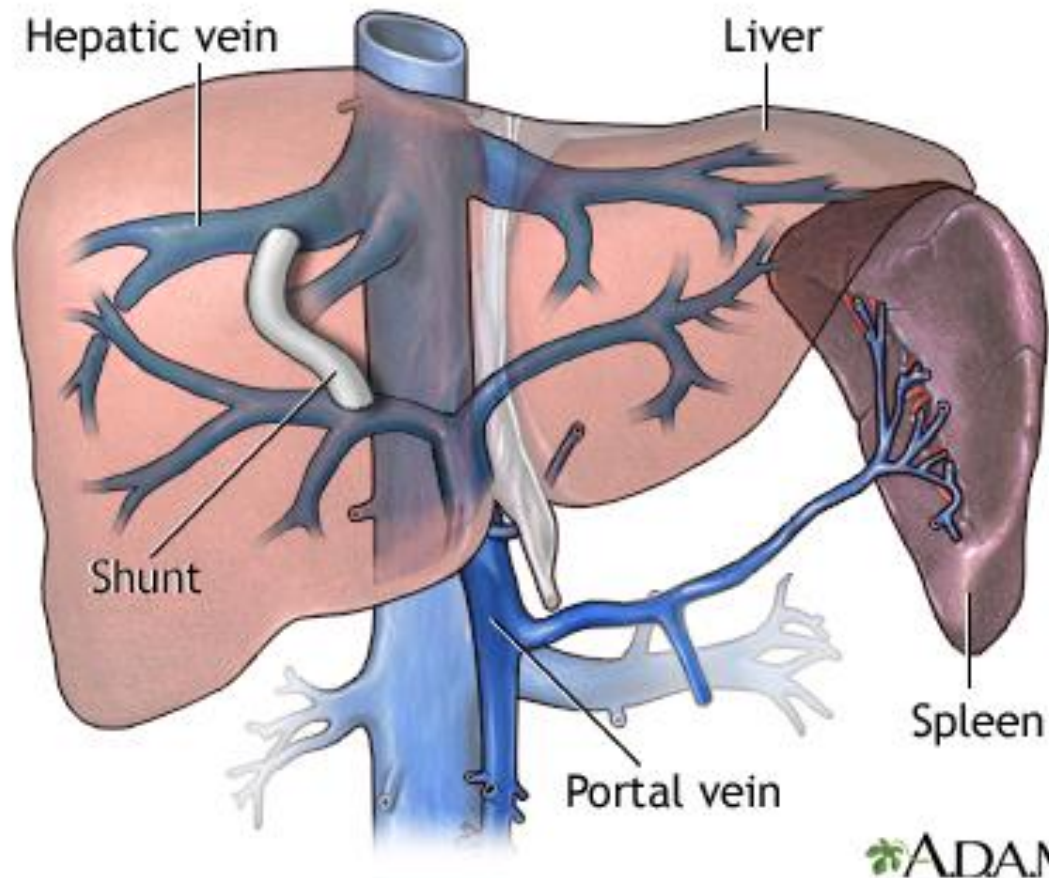
Obstruction of all
hepatic vein

Severe
coagulopathy

Thrombocytopenia

Hepatic
encephalopathy


Stent



Intraprocedural Complications



ACUTE
HEMORRHAGE



LIVER CAPSULE
DAMAGE



TIPS MAL-
DEPLOYMENT

Post Procedure Care: Initial



- Observation at least 6 hours post TIPS



- Laboratory studies: CBC, INR, liver chemistries within 72 hours or sooner if acute liver failure is suspected



- Initial imaging: baseline doppler 3-7 days post to confirm patency

Post Procedure Care: Medication

- Medication adjustments are based on indication
- Variceal bleeding → continue Octreotide 24-48 hours post then discontinue if bleeding stops
- Refractory ascites → continue 2-gram NA restriction and Pre-TIPS diuretic regimen initially
- Taper diuretics slowly over several months if ascites does not reaccumulate

Post Procedure Care: Surveillance



Goal is to detect TIPS stenosis before symptoms



Liver ultrasound and doppler is test of choice ^(15, 16)



Liver ultrasound with doppler study between 3-6 months after TIPS



Then 6- month intervals for long term (along with HCC screening)



Ultrasound shows stenosis à angiogram with pressure gradient measurement. If PSG >12 mmHg patients are at risk for bleeding

Post Procedure Complications: Hepatic Encephalopathy

Etiology & Incidence

- Occurs due to the shunting of blood from the portal to systemic circulation
- 30-50% and chronic HE may occur in up to 25% of patients

Risk Factors

- Hyponatremia, sarcopenia, older age, prior history of HE, large shunt diameter > 10mm, and alcohol related cirrhosis, MELD score

Post Procedure Complications: HE cont.

2-3 weeks post TIPS

> 6 weeks is typically caused by GI bleeding

Rifaximin prophylaxis if patient has risk factors

Primary prophylaxis not recommended due to studies showing mixed data on benefit

Treatment same as in other settings

When HE develops de novo or worsens after TIPS → evaluate for precipitating factors

If refractory to medical therapy may need to have the shunt size reduced

Post Procedure Complications: Cardiac Failure

- Occurs from large volume blood shifts from the splanchnic to systemic circulation causing increased venous return to the heart, cardiac output, and right heart pressure
- This increased venous return can reveal an undiagnosed cardiomyopathy or worsen porto-pulmonary hypertension
- Despite this volume overload, most patients can recover in the several months after TIPS
- Pre-TIPS ECHO can help evaluate

Post Procedure Complications: Liver failure

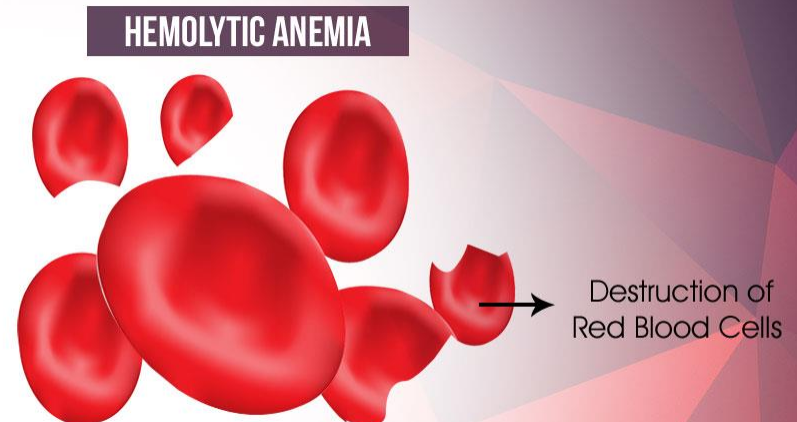
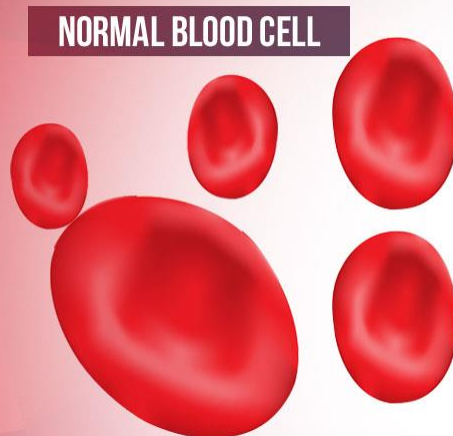
- Incidence 20%
- Defined as > 3 -fold increase in total bilirubin and/or > 2 -fold INR elevation
- Associated with need for transplant or worse mortality
- Anticipate precipitants post TIPS: sepsis, GI bleeding, iatrogenic liver injury, inability to increase arterial blood flow to the hepatic sinusoids

Post Procedure Complications: Infection & Dysfunction

- Very rare
- Due to endovascular shunt infection or periprocedural sepsis
- Sources are the GI track and skin
- Associated with high mortality rate of 32%
- TIPS dysfunction defined as loss of decompression of the portal venous system due to occlusion or stenosis of the TIPS
- If patients show evidence of portal hypertension, think TIPS dysfunction!

Post Procedure Complications: Hemolytic Anemia

- Rare
- Defined as new onset hemolysis with or without anemia without alternate causes (29)
- Spontaneous resolution usually within 8-12 weeks



Case Study #1

45-year-old male with a history of NASH cirrhosis comes to clinic for follow up. He has ascites and is going for paracentesis every 2 weeks. On Furosemide 20 mg daily and Aldactone 50 mg daily. Renal function is preserved. Your next best step is:

1. Optimize their diuretics and emphasize 2-gram sodium restricted diet
2. Place a peritoneal drain
3. Refer them for TIPS evaluation
4. Refer patient for EGD

Case Study #2

Your patient had a TIPS in 2018 for variceal bleeding. You are reviewing their recent imaging for HCC surveillance and note that they have a moderate amount of ascites. The next most important step is:

1. Send patient for EGD and colonoscopy
2. Obtain a doppler study to evaluate for TIPS stenosis and start diuretics
3. Perform a urine toxicology for drugs
4. Order an AFP

Case Study #3

Patient is a 67 yo WM w/ PMH of DM, HTN, HLD, EV, gastropathy, anemia, CAD s/p cardiac stent. He reports an episode of hematemesis that occurred 6 months ago which prompted an ER visit. It was during this admission that he became aware of his liver disease. He has now developed recurrent large EV and refractory ascites. He was referred to you for TIPS evaluation.

What would you screen him for? Diagnostic tests?

References

1. Vangeli M, Patch D, & Burroughs, AK. Salvage TIPS for uncontrolled variceal bleeding. *Journal of Hepatology*. 2002; 37 (5): 703.
2. Zhu Y, Wang X, Xi X, Luo A, & Yang L. Emergency Transjugular Intrahepatic Portosystemic Shunt: An effective and safe treatment for uncontrolled variceal bleeding. *Journal of Gastrointestinal Surgery*. 2019; 23 (11): 2193.
3. Monesceillo A, Martinez-Lagares F, Ruiz-del-Arbol L, Sierra A, Guevara C, Jimenez E...& Pena, E. Influence of portal hypertension and its early decompression by TIPS placement on the outcome of variceal bleeding. *Hepatology*. 2004; 40 (4): 703.
4. Garcia-Pagan J, Di Pascoli M, Caca K, Laleman W, Bureau C, Appenrodt B, Luca, A...& Bosch J. Use of early TIPS for high-risk variceal bleeding: results of a post-RCT surveillance study. *Journal of Hepatology*. 2013; 58 (1): 45.
5. Njel B, McCarty T, & Laine L. Early transjugular intrahepatic portosystemic shunt in US patients hospitalized with acute esophageal variceal bleeding. *Journal of Gastroenterology & Hepatology*. 2017; 32 (4): 852.
6. Conejo I, Guardascione MA, Tandon P, Cachero A, Castellote J, Abraldes JG...& Augustin S. Multicenter external validation of risk stratification criteria for patients with variceal bleeding. *Clinical Gastroenterology & Hepatology*. 2018; 16 (1): 132.
7. Lv Y, Yang Z, Lui L, Li K, He C, Wang Z...& AVB-Tips Study group. Early TIPS with covered stents versus standard treatment for acute variceal bleeding in patients with advanced cirrhosis: a randomized control study. *Lancet Gastroenterology and Hepatology*. 2019; 4 (8): 587.
8. Afdhal NH & Curry MP Early TIPS to improve survival in acute variceal bleeding. *New England Journal of Medicine*. 2010; 365 (25): 2421.
9. Huang YH, Yeh HZ, Chen GH, Chang CS, Wu CY, Poon SK... & Yang SS. Endoscopic treatment of bleeding gastric varices by N-butyl 2-cyanoacrylate (Histoacryl) injection: long term efficacy and safety. *Gastrointestinal Endoscopy*. 2000; 52 (2): 160.
10. Lee YT, Chan FK, Ng EK, Leung VK, Law KB, Yung MY... & Sung JJ. EUS-guided injection of cyanoacrylate for bleeding gastric varices. *Gastrointestinal Endoscopy*. 2000; 52 (2): 168.
11. Chau TN, Patch D, Chan YW, Nagral A, Dick R, & Burroughs, AK. *Gastroenterology*. 1998; 114 (5): 981.
12. Boyer TD, Haskal ZJ. American Association for the Study of Liver Diseases. *Hepatology*. 2010; 51 (1): 3016.
13. Lebrec D, Guily N, Hadengue A, Vilgrain V, Moreau R, Poynard T... & Erlinger S. Transjugular intrahepatic portosystemic shunt: comparison with paracentesis in patients with cirrhosis and refractory ascites: a randomized trial. *Journal of Hepatology*. 1996; 25 (2): 135.

14. Sanyal AJ, Genning C, Reddy KR, Wong F, Kowdley KV, Benner K... & North American Study for the treatment of refractory ascites group. The North American Study for the treatment of refractory ascites. *Gastroenterology*. 2003; 124 (3): 634.
15. Feldstein VA, Patel MD, LaBerge JM. Transjugular intrahepatic portosystemic shunts: accuracy of doppler US in determination of patency and detection of stenosis. *Radiology*. 1996; 201 (1): 141.
16. 16. Kanterman, R.Y., Darcy, M.D., Middleton, W.D., Sterling, K.M., Teefey, S.A., & Pilgram, T.K. (1997). Doppler of sonography findings associated with transjugular intrahepatic portosystemic shunt malfunction. *AJR American Journal Roentgenol*. 1997; 168 (2): 467.
17. Nardelli S, Gioloa S, Pasquale C, Pentassuglio I, Farcomeni A, Merli M... & Riggio O. Cognitive impairment predicts the occurrence of hepatic encephalopathy after transjugular intrahepatic portosystemic shunt. *American Journal of Gastroenterology*. 2016; 111 (4): 523.
18. Sanyal AJ, Freedman AM, Shiffman ML, Purdum PP, Luketic VA, & Cheatham AK. Portosystemic encephalopathy after transjugular intrahepatic portosystemic shunt: results of prospective controlled study. *Hepatology*. 1994; 20 (1): 46.
19. Riggio O, Merli M, Pedretti G, Servi R, Meddi P, Lionetti R... & Capocaccia L. Hepatic encephalopathy after transjugular intrahepatic portosystemic shunt: incidence and risk factors. *Digestive Disease Science*. 1996; 41 (3): 578.
20. Bureau C, Thabut D, Jezequel C, Archambeaud I, D'Alteroche L, Dharancy S... & Vinel JP. The use of rifaximin in the prevention of overt hepatic encephalopathy after TIPS: A randomized control trial. *Annals of Internal Medicine*. 2021; 174 (5): 633.
21. Vilstrup H, Amodio P, Bajaj J, Cordoba J, Ferenci P, Mullen KD... & Wong P. Hepatic encephalopathy in chronic liver disease: 2014 Practice Guidelines by the AASLD and the European Association for the Study of Liver. 2014; 60 (2): 715.
22. Riggio O, Masini A, Efrati C, Nicolao F, Angeloni S, Salvatori FM... & Merli M. *Journal of Hepatology*. 2005; 42 (5): 674.
23. Neff G & Zachry W. Systematic review of the economic burden of overt hepatic encephalopathy and pharmaeconomic impact of rifaximin. *Pharmacoeconomics*. 2018; 36 (7): 809.
24. Fili D, Falletta D, Luca A, Hernandez-Baravoglia C, Clemenza F, Miraglia R.... & Bosch J. Circulatory response to volume expansion and transjugular intrahepatic portosystemic shunt in refractory ascites: Relationship with diastolic dysfunction. *Digestive Liver Disease*. 2015; 47 (12): 1052.
25. Huonker M, Schumacher YO, Ochs A, Sorichter S, Keul J, & Rossie M. Cardiac function and haemodynamics in alcohol cirrhosis and effects of the transjugular intrahepatic portosystemic stent shunt. *Gut*. 1999; 44 (5): 743-8.

References

26. Zheng, M., Chen, Y., Bai, J., Zeng, Q., You, J., Jin, R... & Du, Z. (2008). Transjugular intrahepatic portosystemic shunt versus endoscopic therapy in the secondary prophylaxis of variceal re-bleeding in cirrhotic patients: meta-analysis update. *Journal of Clinical Gastroenterology*, 42(5), 507.
27. Jansen C, Schroder A, Schueler R, Lehmann J, Praktijnjo M, Uschner FE... & Trebicka J. Left ventricular longitudinal contractility predicts acute on chronic liver failure development and mortality after transjugular intrahepatic portosystemic shunt. *Hepatology Communication*. 2019; 3 (3): 340.
28. Garcia-Zamolloa A, Gomez JT, & Egusquiza AC. New cases of endotipsitis: Urgent need for clinical practice guidelines. *Eurasian Journal of Medicine*. 2017; 49 (3): 214.
29. Sanyal AJ, Freedman AM, Purdum PP, Shiffman ML, & Luketic VA. The hematologic consequences of transjugular intrahepatic portosystemic shunts. *Hepatology*. 1996; 23 (1): 32.
30. Patidar K R, Sydnor M, & Sanyal AJ. Transjugular intrahepatic portosystemic shunt. *Clinics in Liver Disease*. 2014; 18 (4): 85-876. <https://doi.org/10.1016/j.cld.2014.07.006>.
31. Rajesh S, George T, Philips CA, Ahamed R, Kumbhar S, Mohan N, Mohanan M, & Augustine P. Transjugular intrahepatic portosystemic shunt in cirrhosis: An exhaustive critical update. *World Journal of Gastroenterology*. 2020; 26 (37): 5561-5596. <https://www.wjgnet.com/1007-9327/full/v26/i37/5561.htm>.
32. Sankar K, Moore CM. Transjugular Intrahepatic Portosystemic Shunts. *JAMA*. 2017; 317 (8): 880. doi:10.1001/jama.2016.20899.
33. Fanelli F. The Evolution of Transjugular Intrahepatic Portosystemic Shunt: Tips. *ISRN Hepatol*. 2014 Mar 18; 762096. doi: 10.1155/2014/762096. PMID: 27335841; PMCID: PMC4890882.
34. Rösch J, Hanafée WN, Snow H. Transjugular portal venography and radiologic portacaval shunt: an experimental study. *Radiology*. 1969 Apr; 92 (5): 1112-4. doi: 10.1148/92.5.1112. PMID: 5771827.
35. Saad WE. The history and future of transjugular intrahepatic portosystemic shunt: food for thought. *Seminars in Interventional Radiology*. 2014; 31 (3): 258-261. <https://doi.org/10.1055/s-0034-1382794>.
36. Bercu ZL, & Fischman AM. Outcomes of transjugular intrahepatic portosystemic shunts for ascites. *Seminars in Interventional Radiology*. 2014; 31 (3): 248-251. <https://doi.org/10.1055/s-0034-1382792>.