



GHAPP

Gastroenterology & Hepatology
Advanced Practice Providers

2021 Fourth Annual National Conference

September 9-11, 2021

Red Rock Hotel – Las Vegas, NV

Post-TIPS Patient Management

Sherona Bau, ACNP
The Pflieger Liver Institute UCLA
Los Angeles, CA

Disclosures

All individuals involved in control of the content of continuing education activities provided by the Annenberg Center for Health Sciences at Eisenhower are required to disclose to the audience any real or apparent commercial financial affiliations related to the content of the presentation or enduring material. Full disclosure of all commercial relationships must be made in writing to the audience prior to the activity. All staff at the Annenberg Center for Health Sciences at Eisenhower and Gastroenterology and Hepatology Advanced Practice Providers have no relationships to disclose.

Disclosures

Sherona Bau, ACNP

No financial relationships to disclose.

Introduction

- Review a case study
- Analysis of ascitic fluid
- Calculation of SAAG (serum ascitic albumin gradient) and SBP (spontaneous bacterial peritonitis)
- Management of ascites
- Brief introduction about TIPs (transjugular intrahepatic portosystemic shunt)
- Complications of TIPs
- TIPs management

Case Study

- Mr. FW is a 66 years old man with history of liver cirrhosis secondary to chronic hepatitis B. His liver disease is complicated by HCC. He was not a candidate for resection or transplant in Jan 2020 because of tumor size 12x12 cm and thrombus in portal vein. He presents with 20 lbs weight gain in 3 months, nausea, fatigue, abdominal distention. (Na-MELD 11)
- PMH: HBV, HCC, TB exposure
- PSH: cholecystectomy 2009
- Medication: Tenofovir alafenamide 25mg daily, Tramadol 50mg every 6 hours prn for pain, lactulose 30 cc bid, Lenvatinib 8mg

Case Study

- Family history: No family history of liver disease
- Social history: He drank hard liquor and wine on daily basis. He quit in April 2019. He does not smoke or use IVD.
- Review of Systems: 14 points ROS obtained. Pertinent positive noted above

Case Study

- Physical Exam: BP 119/72, HR 87, T 97.6 F, Ht 6'1, 202 pounds, O2 sat 98%
 - General NAD
 - Heart: RRR
 - Abdomen: palpable liver edge 3 fingers below right costal margin, + shifting dullness, + superficial abdominal collaterals
 - Extremities: Trace edema on BLE
 - Neurologic: A&O x 4, no gross asterixis
- **Which tests/labs should be ordered?**

Tests/Labs to Order

- Abdominal ultrasound to confirm ascites
- Ultrasound guided paracentesis
- Lab:
 - Hepatic function panel
 - BMP
 - CBC with plt
 - INR
 - AFP
 - HBVDNA
 - BNP

Tests/Labs to Order

- Ascitic fluid analysis
 - Protein, total fluid
 - Albumin, fluid
 - Cell count, fluid
 - Bacterial culture-grain stain, fluid
 - Mycobacteria PCR, body fluid
 - Cytology, fluid

Results of Tests/Labs

- US of abdomen:
 - Moderate volume ascites, likely stigmata of portal hypertension
 - Advanced cirrhosis

Results of Tests/Labs

- Hepatic function panel : Total protein 7.3, **Albumin 2.9**, total bil 1.1, bilirubin conjugated 0.7, alkaline phosphatase 128, AST 31, ALT 22
- BMP: Na 140, K 3.4, Cr 0.7, BUN 13, Glucose 180
- CBC with plt: WBC 8.68, Hgb 8.7, Hct 24.9, Plt 104
- INR: 1.4
- AFP: 4.2
- HBVDNA: not detected
- BNP: 67

Results of Tests/Labs

- Ascites fluid analysis
 - Protein, total fluid – **1.8 g/dL**
 - Albumin, fluid – 0.6 g/dL
 - Cell count, fluid – PMN 22.5/mm
 - Bacterial culture – grain stain, fluid – no bacteria seen
 - Mycobacteria PCR, body fluid – M Tuberculosis complex, PCR not detected
 - Cytology, fluid – negative for malignant cells
 - SAAG (serum albumin (2.9) – ascitic albumin (0.6)) **2.3g/dL**

Body Fluid Count & Diff

- RBC 1,000
- **WBC 250**
- **Segmented neutrophil 9%**
- Lymphocyte 21%
- Monocyte 67%
- Mesothelial 3%
- Total cells 100 cells

SAAG and SBP Calculation

- **SAAG** – Serum ascites albumin gradient
- Formula of SAAG = serum albumin – ascites albumin (2.9-0.6) = 2.3 g/dL
- **SBP** –Spontaneous bacterial peritonitis
- If absolute PMN (polymorphonuclear leukocytes) count in ascitic fluid $\geq 250/\text{mm}^3$, it is positive for SBP
- Formula of PMN (WBC x % of segmented neutrophil) (250 x 9%) = PMN 22.5/mm³

SAAG & Total Protein Analysis

- Liver:
 - High SAAG ≥ 1.1 g/dL
 - Low total protein ≤ 2.5 g/dL
- Cardiac:
 - High SAAG ≥ 1.1 g/dL
 - High total protein ≥ 2.5 g/dL
- Nephrotic:
 - Low SAAG <1.1 g/dL
 - Low total protein ≤ 2.5 g/dL

Differential Diagnosis

- Ascites secondary to
 - Decompensated liver cirrhosis
 - Congestive heart failure
 - Tuberculosis
 - Chronic renal disease
 - Hepatocellular carcinoma

Diagnosis

Ascites secondary to
**Decompensated liver cirrhosis (high SAAG,
low total protein)**

- Congestive heart failure
- Tuberculosis
- Chronic renal disease
- Hepatocellular carcinoma

Management of Ascites

- Medical management
 - Furosemide 40mg po daily
 - Spironolactone 100mg po daily
 - Lab in 1 week after starting diuretics
- Daily weight
- Low Sodium diet < 2000 mg per day
- Procedure Management
 - Paracentesis
 - Albumin 25% infusion

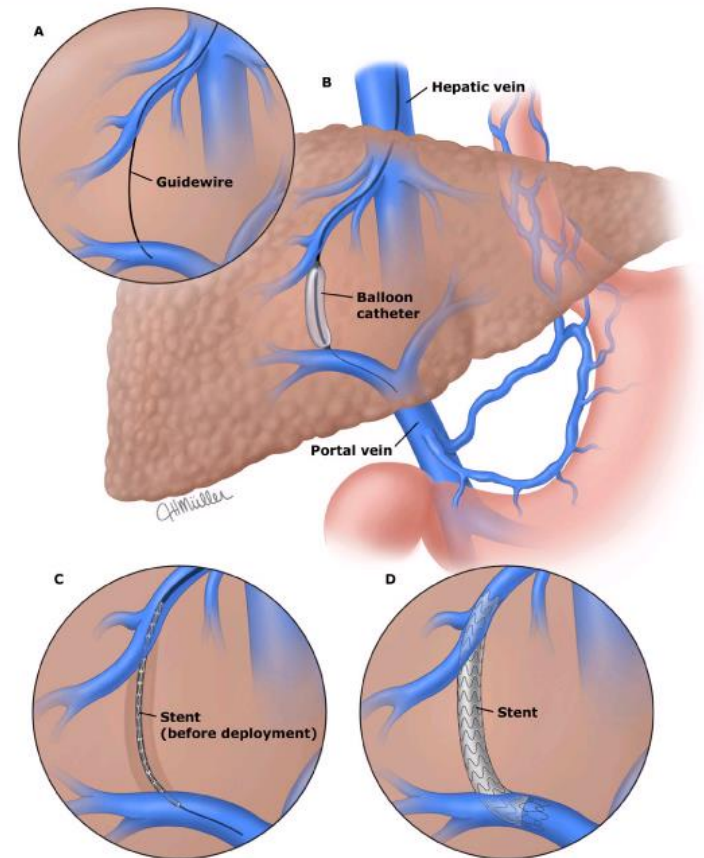
Management

- Unfortunately, patient fails medical management because of hyponatremia and he requires paracentesis every 7 to 10 days for 5 months. He also has sarcopenia.
- Mr. FW underwent Transjugular intrahepatic portosystemic shunt (TIPS) on 4/28/21.

TIPS (Transjugular Intrahepatic Portosystemic Shunt)

The transjugular intrahepatic portosystemic shunt (TIPS) is created by passing a needle catheter via the transjugular rout into the hepatic vein and wedging it in there. The needle is then extruded and advanced through the liver parenchyma to the intrahepatic portion of the portal vein and a stent is placed between the portal and hepatic veins. A TIPS functions like side-to-side surgical portocaval shunt, but does not require general anesthesia or major surgery for placement. (A) Passage of a guidewire between the hepatic vein and the portal vein. (B) Inflation of a balloon catheter within the liver to dilate the tract between the hepatic vein and the portal vein. (C) Deployment of the stent. (D) Stent in its final position.

Transjugular intrahepatic portosystemic shunt



Post -TIPs Management

- Abdominal ultrasound with Doppler 1 month after TIPs to check patency, then every 6 months
- Follow up appointment with the patient 1-2 weeks after TIPs to closely monitor presentation of hepatic encephalopathy
- Monitor signs of liver failure such as total bilirubin ≥ 3 fold or INR ≥ 2 fold

Complications After TIPS

- Hepatic encephalopathy ~ 30-50%
- Liver failure ~ 20%
- Cardiac failure ~ 20%
- Infection, uncommon
- TIPs dysfunction ~ 12%

Case Study

- On 5/7/21 (10 days after TIPs), Mr. FW and his daughter are in the clinic. Ascites is resolved, no more paracentesis since 4/28/21.
- However, Mr. FW does not like to take lactulose per his daughter.
- Start Rifaximin 550mg bid on 5/7/21
- Admitted to the hospital because of HE on 5/17/21

Case Study

- Mr. FW is found medication non-adherence to lactulose. He does not like the taste of lactulose. His mental status is significantly improved after increase frequency of bowel movement while he is in the hospital.
- Mr. FW is admitted to the hospital again on 7/5/21 secondary to altered mental status.
- Patient again does not take lactulose for 2 days because he has diarrhea and nausea.

Case Study

- Mr. FW is instructed to take lactulose BID to TID (goal is to titrate up to 3 BM per day). He was taking TID and had 7 BM per day, so he stopped lactulose.
- UTI is ruled out
- Daughter reports that Mr. FW hides his medication

Patient Follow-Up

- Patient Care
 - Short-term plan and long-term plan
 - Closely monitor patient every 10-14 days. Reinforce medication compliance
 - Continue lactulose 30 cc BID to TID to titrate up to 3 BM per day
 - Continue rifaximin 550mg bid
 - Lab CMP, CBC with plt, INR, AFP, HBVDNA
 - US abdomen with Doppler every 6 months

Patient Follow-Up

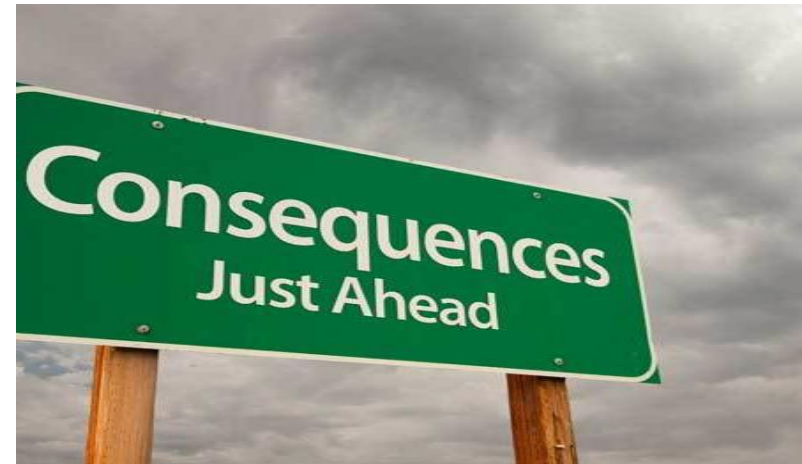- Patient Care
 - Short-term plan and long-term plan
 - MRI of abdomen every 3 months to monitor his HCC (for all patients who underwent locoregional treatment for HCC)
 - Low sodium diet < 2000 mg per day
 - Follow up with oncology
 - Follow up with IR
 - Needs to establish care with PCP

Summary

- Need to determine if ascites is from liver etiology
- TIPs is considered an option if patient failed medical management of ascites or patient developed refractory ascites
- Major complication after TIPs is encephalopathy, can be up to 1 year, may require TIPs revision
- Family members should monitor sleep cycle or behavior change
- Lactulose and Rifaximin should be ordered if patient develops encephalopathy
- Need to check TIPs patency with Doppler ultrasound 1 month after TIPs and every 6 months for life

Tips Procedure – An Intervention With Many Potential Consequences

- Justin M. Potter, MSN, AGACNP-BC
- Transplant Hepatology
- Mayo Clinic Hospital
- Phoenix, AZ.



Disclosures

Justin M. Potter, MSN, AGACNP-BC

No financial relationships to disclose.

Objectives

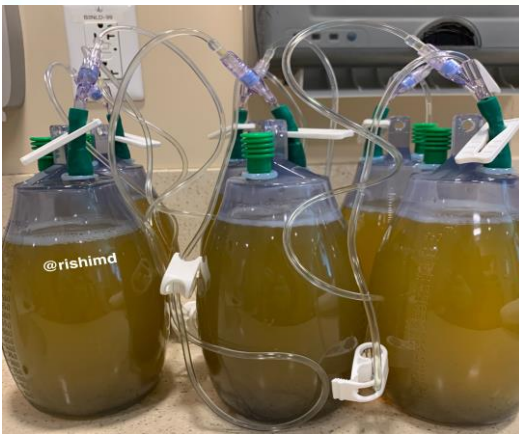- Define Post Transplant Ascites
- Obtaining Hepatic Venous Pressure Gradient and Prognostic Value
- Identifying significant Liver Injury Post TIPS procedure
- Identify an uncommon/underrecognized complication post TIPS
- Considerations for Liver Transplant



Case Study

- 38 yo Male with PMHx AIH/PSC overlap s/p DCD DDLT in 2/2021
- Post Tx course c/b rising liver injury tests with concern for rejection vs biliary obstruction
- Liver Biopsy revealed ACR (RAI 6/9) and features of biliary outflow obstruction. ACR – steroid responsive.
- MRCP performed without evidence of biliary obstruction – subsequent ERCP performed 2/2 cholestatic pattern of liver injury showed no evidence of biliary strictures, casts or debris within the ducts, no stents or balloon angioplasty performed.

Post Transplant Ascites



- Presented to the ED in early 4/2021 with abdominal distention + SOB.
- Found to have a moderate amount of ascites – Paracentesis performed
 - 3.3L of straw colored ascitic fluid removed
 - Serum ascites albumin gradient (SAAG) – 1.3 c/w pHTN
 - Triglycerides – 84
 - Non-neutrocytic – No SBP by cell count or culture
 - **NEXT STEPS?**

TJ Liver Biopsy With Pressure Gradient Assessment

Pressure Gradient Assessment

- Wedged Hepatic Venous Pressure (WHVP) – Free Hepatic Venous Pressure (FHVP) = Hepatic Venous Pressure Gradient (HVPG) – Also called portosystemic gradient (PSG)
- WHVP 15 – FHVP 4 = 11mmHg

Pathology

- Negative for acute cellular rejection
- Resolution of the features of biliary outflow impairment
- Early changes of Nodular Regenerative Hyperplasia (NRH) – Non cirrhotic pHTN 6 weeks post LT.

Considerations

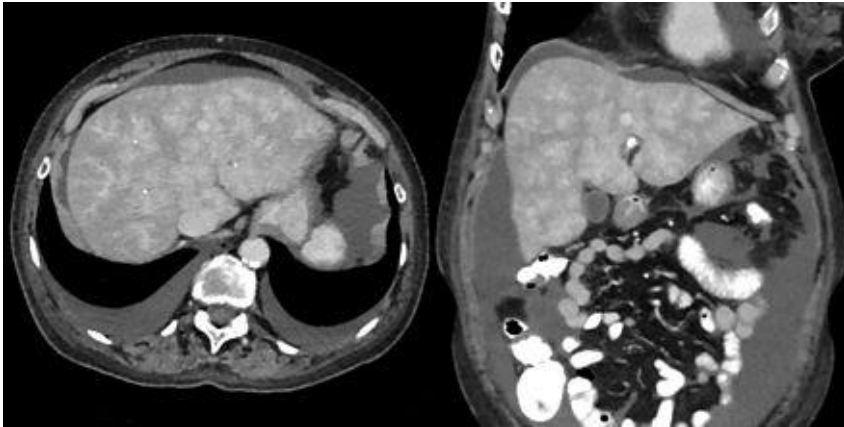
- Hepatic vein patency
- Right sided failure
- Portosystemic fistula

NEXT STEPS

- IR Venography
- Rule out Fistula
- Echocardiogram

Prognostic Value of HVPG in Patients with Chronic Liver Disease	
Measurement	Significance
1-5 mm Hg	Normal
≥ 6 mm Hg	Risk of disease progression in persons with HCV recurrence after liver transplantation
≥ 10 mm Hg	Clinically significant portal hypertension
≥ 12 mm Hg	Increased risk for rupture of varices
≥ 16 mm Hg	Increased risk mortality
≥ 20 mm Hg	Treatment failure and mortality in acute variceal bleeding

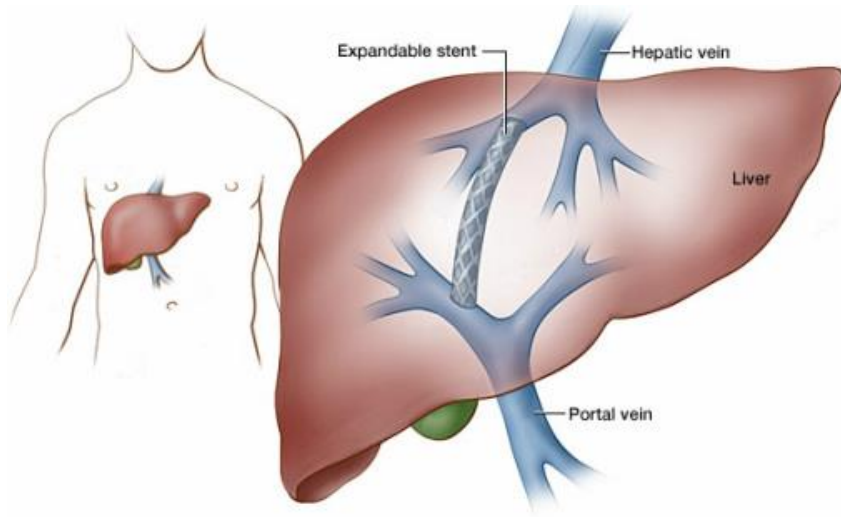
Investigations



Echo – Normal EF, normal Right atrial pressure and no signs of right sided failure.

- IR Venogram
 - Wedged Hepatic Venous Pressure: **27mmHg!** (Hepatic Congestion) - ? AV fistula
 - Free Hepatic Venous Pressure: 13mmHg
 - HVPg – 13mmHg (PSG increased)
 - Right Atrial Pressure (CVP) – 4mmHg
- 3 Phase CT
 - No AVF noted, Nutmeg appearance of Hepatic parenchyma c/w congestive hepatopathy, hepatic veins diminutive (Budd Chiari physiology) – recent US argued against this, Large volume ascites.
- IR Mesenteric Artery Angiogram
 - No fistula noted within the PV, Celiac, hepatic, splenic, SMA or IMA.

Transjugular Intrahepatic Portosystemic Shunt (TIPS)



- Pre TIPS Pressure Gradient Assessment – HVPG 18mmHg
- Post TIPS Pressure Gradient Assessment – HVPG 11mmHg

LABS	Pre TIPS 4/19	Post TIPS D1 4/20	D2 – 0100 4/21	D2 – 1300 4/21	D3 – 0300 4/22
ALT	70	421	1954	2260	2896
AST	50	713	3341	4068	2990
TB	0.5	1.1	2.4	2.4	2.5
INR	1.1	1.7	3.5	2.2	1.8
Na	121	126	125	126	125
Lactate		4.4	7.4	6.7	2.4

Transferred to ICU 4/20-4/21 febrile, tachycardic, HoTN, acidotic, and ischemic hepatitis. Required vasopressor support, pancultured, and placed on broad spectrum antibiotics.

Relisted for LT on 4/21 – MELD 30

	Blood Cx 1/2	Blood Cx 2/2	Peritoneal Cx
4/20	E. Faecalis	E. Faecalis	E. Faecalis
4/21	E. Faecalis	E. Faecalis	NGTD
4/23	E. Faecalis	E. Faecalis	
4/25	E. Faecalis/Candida Glabrata (30hrs)	E. Faecalis/Candida Glabrata(29 hrs)	NGTD
4/26	E. Faecalis/Candida Glabrata (32hrs)	E. Faecalis/Candida Glabrata (33hrs)	NGTD
4/27	NGTD	NGTD	



Infectious Workup

- Repeat Paracenteses – 4/21, 4/25, 4/26 – Non-neutrocytic and culture negative
- Hepatic/Abd Doppler US – no dilated ducts, no fluid collection, large volume ascites. TIPS patent.
- CT abdomen and pelvis – no dilated ducts, no abscess within the liver or abdomen.
- TEE – negative for any valvular vegetations
- Line Removal – NGTD
- Tagged WBC

Diagnosis:

- Intermittently febrile, persistent bacteremia despite escalation of antibiotics, now with fungemia. Clinically stable and out of the ICU since 4/23.
- **Endotipsitis/TIPSitis**
 - “Gold Standard” – removal of stent to identify source, only possible during LT or autopsy
 - “Definite infection” – clinically significant persistent bacteremia (fever and multiple positive blood cultures) along with vegetations of thrombi within the stent
 - “Probable infection” – sustained bacteremia and unremitting fever in a patient with apparently normal TIPS without any identifiable source of infection

To Transplant or Not to Transplant?

1. Was this graft going to recover? (Ischemic injury, infection, still with clinically significant pHTN)
2. Would we be able to treat with systemic antibiotics/antifungals and clear the infection?
3. What would organ offers look like in the future? Native MELD score 16, listed with MELD 30 until tomorrow? DCD organ offered on last day prior to recertifying MELD score.
4. Should we wait for negative blood cultures for at least 48-72hrs as recommended by Infectious Disease experts?
5. Should we transplant with active bacteremia/fungemia knowing the risks associated with increased IS at time of Transplantation?



Outcome

Repeat Liver Transplant on 4/28

- DCD OLT on 5/28, WIT 20 minutes, CIT 5hrs 9 minutes
- EBL 10L required 31units of PRBC, 13 units of FFP, 4 cryo, and 2 platelets
- Post op course c/b chylous ascites requiring TPN, severe protein malnutrition, and recurrent bacteremia/fungemia which resolved with antibiotics/antifungals and line removal

Explant Pathology

- Negative for ACR
- Severe preservation reperfusion injury with marked centrilobular hepatocyte dropout, secondary changes of hyperplasia.
- Biliary stasis



Summary

- Post Transplant Ascites 2/2 to NRH with significant portal HTN.
- HVPG increasing despite attempting medical management to control portal HTN.
- Significant Liver Injury post TIPS with transaminitis in the thousands, poor synthetic function (INR 3.5).
- Further complicated by probable TIPStitis (estimated around 1%) and thought to be underdiagnosed with high mortality rate associated with Staph and candida species
- Decision to Re-Transplant was difficult, ultimately successful

Vettakkara K.M. Niyas, Vishakh C. Keri, Prabhat Kumar, Endotipsitis: An Underdiagnosed Complication of Transjugular Intrahepatic Portosystemic Shunts, Journal of Clinical and Experimental Hepatology, 2021

Questions?

EMAIL: POTTER.JUSTIN@MAYO.EDU